

Healing of Amyotrophic Lateral Sclerosis: A Case Report

Inge Mangelsdorf^a Harald Walach^b Joachim Mutter^{c,d}

^aToxikologie-Gesundheitsberatung, Hamburg, Germany;

^bDepartment of Psychology, University Witten-Herdecke, Witten, Germany;

^cTagesklinik Konstanz, Konstanz, Germany;

^dParacelsus Clinic, Castaneda, Switzerland

Keywords

Amyotrophic lateral sclerosis ·
Progressive muscular atrophy · Motor neuron disease ·
Chelation therapy · Mercury · Heavy metals

Summary

Background: Amyotrophic lateral sclerosis (ALS) is a devastating disease leading to death within 3–5 years in most cases. New approaches to treating this disease are needed. Here, we report a successful therapy. **Case Report:** In a 49-year-old male patient suffering from muscle weakness and fasciculations, progressive muscular atrophy, a variant of ALS, was diagnosed after extensive examinations ruling out other diseases. Due to supposed mercury exposure from residual amalgam, the patient's teeth were restored. Then, the patient received sodium 2,3-dimercaptopropanesulfate (DMPS; overall 86 × 250 mg in 3 years) in combination with α-lipoic acid and followed by selenium. In addition, he took vitamins and micronutrients and kept a vegetarian diet. The excretion of metals was monitored in the urine. The success of the therapy was followed by scoring muscle weakness and fasciculations and finally by electromyography (EMG) of the affected muscles. First improvements occurred after the dental restorations. Two months after starting therapy with DMPS, the mercury level in the urine was increased (248.4 μg/g creatinine). After 1.5 years, EMG confirmed the absence of typical signs of ALS. In the course of 3 years, the patient recovered completely. **Conclusions:** The therapy described here is a promising approach to treating some kinds of motor neuron disease and merits further evaluation in rigorous trials.

© 2017 The Author(s). Published by S. Karger GmbH, Freiburg

Schlüsselwörter

Amyotrophe Lateralsklerose ·
Progressive Muskelatrophie · Motorneuronenerkrankung ·
Chelat-Therapie · Quecksilber · Schwermetalle

Zusammenfassung

Hintergrund: Amyotrophe Lateralsklerose (ALS) ist eine schwere Erkrankung, die meist innerhalb von 3–5 Jahren zum Tode führt. Neue Wege für die Behandlung werden benötigt. Wir berichten hier über eine erfolgreiche Therapie. **Fallbericht:** Bei einem 49-jährigen männlichen Patienten mit Muskelschwäche in den Extremitäten und Faszikulationen wurde unter Ausschluss verschiedener Differenzialdiagnosen eine progressive Muskelatrophie, eine Variante von ALS, diagnostiziert. Wegen einer vermuteten Amalgambelastung wurde eine umfangreiche Zahn- und Kiefersanierung durchgeführt. Dann erhielt der Patient ein 1,3-Dimercaptopropansulfonat (DMPS; 86 × 250 mg in 3 Jahren) in Kombination mit α-Liponsäure, gefolgt von Selen. Dazu nahm er Vitamine und Spurenelemente ein und ernährte sich vegetarisch. Die Ausscheidung von Metallen im Urin wurde bestimmt und der Erfolg der Therapie bezüglich der Muskelschwäche und Faszikulationen verfolgt. Schließlich wurde eine Elektromyographie (EMG) der betroffenen Muskeln durchgeführt. Erste Verbesserungen ergaben sich nach der Zahnbehandlung. Zwei Monate nach Therapiebeginn mit DMPS war die Quecksilberkonzentration im Urin erhöht (236,4 μg/g Kreatinin). Nach 1,5 Jahren fanden sich in der EMG keine ALS-typischen Befunde mehr, und im Verlauf von 3 Jahren gesundete der Patient völlig. **Schlussfolgerungen:** Die hier beschriebene Therapie könnte für manche ALS-Erkrankungen erfolgreich sein und sollte in weiteren Untersuchungen gründlich überprüft werden.

Table 1. Timeline

Year	Diseases, diagnoses, interventions, important life events
1965–1990	various vaccinations including tetanus, pertussis, polio, hepatitis A, diphtheria, cholera
1970–1985	dental caries, received 16 amalgam fillings
1999	removal of dental amalgam fillings without protection; replaced by denture of gold (5) and ceramics (8)
2003	vaccination: tetanus, polio, and diphtheria
2004	vaccination: hepatitis A
2004	sports injury: hit in the neck and subsequent meningomyeloencephalitis caused by herpes zoster, prolapsed cervical disk
2005	vaccination: tick-borne encephalitis
2008	got a tattoo (6 × 20 cm, lower arm)
2008	vaccination: tick-borne encephalitis, hepatitis A + B
2010–2011	divorce
10/2012	weakness in arms and legs, fasciculations, more frequent urination
12/2012	resident neurologist: transfer to neurological inpatient unit for further diagnosis
01/2013	neurological inpatient unit: diagnosis of PMA based on clinical findings, EMG, electroneurography, MRI, investigation of spinal fluid, blood parameters
02/2013	clinic of J.M.: further diagnoses; start of therapy with vitamins, micronutrients, and other supplements
03/2013	dental treatment: removal of metals, curing of osteitis
03/2013	first signs of improvement, increased strength in thigh
03/2013	start of chelation therapy
04/2013	start of psychotherapy
05/2013	removal of titanium screws in knee
09/2013	removal of tattoo
10/2014	absence of typical signs of motor neuron disease confirmed by resident neurologist by EMG
04/2017	further improvements and good health

EMG = Electromyography; PMA = progressive muscle atrophy; MRI = magnetic resonance imaging.

Introduction

Amyotrophic lateral sclerosis (ALS) is a neurodegenerative disease characterized by selective motor neuron death. Patients develop a progressive muscle phenotype characterized by spasticity, hyperreflexia, fasciculations, muscle atrophy, and paralysis. Depending on the disease variant, upper or lower neurons are damaged, or both [1]. The paralysis progresses affecting more and more muscles and the patients finally die from asphyxia. The median survival time after onset of symptoms is 32 months [2, 3].

Despite considerable progress in understanding the cellular and molecular events in ALS [4], there is no generally accepted therapy besides riluzole, which may prolong survival by only 3 months [5]. Numerous new therapies are currently investigated [6], also including complementary medicine [7], and some of them may be promising. In the clinic of J.M., a plan of treating chronic diseases has been developed that involves eliminating risk factors, especially heavy metals, curing the sources of inflammation, and substituting with micronutrients and diets. Numerous patients have experienced considerable improvements. A case report of a successful treatment for secondary adrenal insufficiency with fibromyalgia has already been published [8]. Here, we report a case where progressive motor neuron disease (PMA), the variant of ALS involving only the lower motor neurons [9], was treated successfully.

Case Report

Presenting Concerns

In October 2012, a 49-year-old male patient (non-smoker, non-drinker, 178 cm, 77 kg) observed a weakness in his right arm following the restarting of martial arts after having paused for 2 years. In December 2012, he experienced additional weaknesses in the left and right shoulder and in the right thigh, and since then he noticed fasciculations in the upper extremities as well as more frequent urination.

Clinical Findings

After initial presentation at a resident neurologist, he was admitted in January 2013 to a neurological inpatient unit, and finally he presented in the clinic of J.M. in February 2013 (for a timeline, see table 1). The following findings were reported by the neurological inpatient unit. There was a slight paresis of the left arm, and the left upper arm was somewhat thinner than the right upper arm. In both arms and in both lower legs fasciculations were observed. In the arms, the intensity decreased from proximal to distal and from left to right. In the pronator drift test, the left arm pronated. The muscle reflexes were weak but more pronounced on one side. Pyramidal signs were negative. The superficial sensibility was unaffected. Fasciculations were also seen in the examinations in the clinic of J.M. in February 2013, as well as weakness of muscles in the left and right shoulder, the right triceps, and the right thigh. Additional symptoms were diarrhea and sleeping disorders.

Disease History

The patient had received numerous vaccinations (table 1); no adverse reactions were reported. In 2004, the patient had suffered from severe meningomyeloencephalitis from a herpes zoster infection: two days after a hit in the neck during combatant sports, the disease started with paralysis of the bladder. Subsequently, the patient developed nausea, loss of vision, fever, somnolence, as well as paresthesia and paralysis of the whole body starting at the thorax level.

Table 2. Differential diagnoses of ALS and corresponding findings in the patient

Disease	Findings in patient that exclude corresponding differential diagnosis
Cervical spondylotic myelopathy	no signs of myelopathy in MRI, several body regions affected, no sensory deficits, no changes in MEP
Multifocal motor neuropathy	no conduction blocks in EMG, anti-GM1 antibodies, also lower extremities involved
Multifocal acquired demyelinating sensory and motor neuropathy (Lewis-Sumner syndrome)	motor nerve conduction normal
Spinal muscle atrophy, adult type = type IV or other myopathies	creatine phosphokinase level not increased
Post-poliomyelitis syndrome	no disease history of polio
Neuralgic shoulder amyotrophy	absence of pain, EMG findings, no sudden onset, C-reactive protein level not increased
Kennedy syndrome	no gynecomastia, no perioral fasciculations
Multiple sclerosis	clinical findings not typical of multiple sclerosis; absence of oligoclonal bands in spinal fluid, normal MEP, no sensory defects
Infections (Lyme borreliosis, Lues, HIV, herpes zoster)	laboratory investigations for Lyme borreliosis negative, no intrathecal antibodies
Metabolic disorders (diabetes mellitus, hyperthyreosis)	glucose, thyroid-stimulating hormone, T3, T4 within normal limits

ALS = Amyotrophic lateral sclerosis; MRI = magnetic resonance imaging; MEP = motor evoked potential; EMG = electromyography; HIV = human immunodeficiency virus; T3 = triiodothyronine; T4 = thyroxine.

The patient could not walk any more, although some leg movements were possible. Later, he had feelings of heat in the back of his legs. Magnetic resonance imaging (MRI) showed several prolapsed cervical discs. Further examinations in a neurologic clinic showed nystagmus, indistinct articulation, highly increased immunoglobulin G (IgG) levels for herpes zoster in the serum, increased protein, IgG, lactate, and a number of lymphocytes in the cerebrospinal fluid. The patient received antiviral and antibacterial therapy. Within 6 weeks, the paralyses diminished gradually. The overall recovery took 3–4 years. With respect to the later diagnosis of ALS in 2012, it is remarkable that no findings were reported in the electromyography (EMG) and in the nerve conduction studies.

Diagnostic Focus and Assessment

In the neurological inpatient unit, the investigations focused on the possibility of a motor neuron disease, investigating the cervical spinal stenosis and addressing the meningomyeloencephalitis diagnosed in 2004. While the MRI scan of the brain showed no abnormalities, the spinal MRI scan showed degenerative changes, i.e. cervical spondylosis with multisegmental spinal stenosis without myelopathy. In the EMG, signs of acute and chronic denervation were found in several muscles:

- Musculus (M.) masseter: chronic denervation;
- M. vastus medialis, right side: acute and chronic denervation;
- M. tibialis anterior, right side: chronic denervation;
- M. gastrocnemius caput lateralis, left side: chronic denervation;
- M. biceps brachialis, left side: chronic denervation;
- M. adductor digiti minimi, right side: chronic denervation;
- M. deltoideus, right side: acute and chronic denervation.

Fasciculations were only detected in the arms and legs. The motor nerve conduction velocity of the ulnar nerve (Nervus (N.) ulnaris) was unchanged while the sensible conduction velocity was decreased on both sides, but to a higher degree at the left side. The motor-evoked potentials of the arms and legs were normal. No F-waves were found in investigations of the N. medianus and N. ulnaris. Electroneurographic examinations of the N. axillaris showed a reduction of the amplitude, which was more pronounced on the left side compared to the right side.

Total protein was slightly increased in the spinal liquor (81.8 mg/dl), resulting from an increase in albumin (54.8 mg/dl). Cell counts, glucose and lactate levels were within the normal limits. Intrathecal antibodies were not detected. Standard laboratory tests were without relevant findings. There were no antibodies to gangliosides in the serum. The creatine phosphokinase levels were

unchanged. In the end, these findings led to the diagnosis of progressive muscle atrophy (PMA) [2]. Table 2 shows the rationale for the exclusion of relevant differential diagnoses.

In February 2013, just after the diagnosis of PMA, the patient presented in the clinic of J.M., where additional parameters in blood and urine were investigated. 25-Hydroxyvitamin D3 (14 µg/l, reference 30–60 µg/l), omega-3 index (4.44, reference > 8), and creatinine in urine (0.28 g/l, reference 0.8–2.0) were decreased. Cystatin C (0.81 mg/l, reference 0.56–0.95 mg/l), however, was within the normal limits, indicating normal glomerular filtration. *Borrelia*-specific IgG and IgM were negative; a later lymphocyte transformation test for Lyme borreliosis was also negative.

Analysis of the history with respect to mercury exposure showed unprotected removal of 16 amalgam fillings in 1999. Exposure to mercury from the preservative thimerosal may have occurred by vaccinations and from the use of contact lens fluids. The analysis of metals in pubic hair, however, provided a mercury concentration within the normal limits and minor changes for copper and iron.

The status of the teeth in February 2013 was as follows: teeth 18, 16, 28, 38, 41, 46, 48 were missing, in the cavitation of the 2 missing teeth 16 and 46, osteonecrosis was observed. Teeth 14, 15, 17, 24–27, 37–35, 44, 45, and 47 had gold or ceramic denture. Three teeth with root canal fillings (25–27) showed apical osteitis.

Therapeutic Focus and Assessment

The therapy aimed at removing all possible sources of inflammation or chronic intoxication. For this purpose, 3 teeth were extracted. Instead, a removable prosthesis was incorporated. The osteitis in the regions of the 2 missing teeth was treated, and the metal denture in the remaining teeth was replaced by zirconium oxide denture. All dental procedures were made with proper safety measures to minimize the patient's exposure to metals and other dental materials, dusts, and fine particles. A black tattoo was removed. Analysis for heavy metals in the removed tissue showed detectable levels of aluminum (850 µg/kg), arsenic (10 µg/kg), lead (60 µg/kg), nickel (850 µg/kg), zinc (400 µg/kg), and tin (100 µg/kg). The mercury levels were below the limit of detection (2.5 µg/kg). In addition, the titanium screws left over in the knee from former surgery were removed because a lymphocyte transformation test and a special test showed type-IV sensitivity to titanium.

After an initial phase of 2 weeks where the patient took only vitamins and micronutrients (table 3), a chelation therapy was started. Once per week the patient received an intravenous (i.v.) infusion of α-lipoic acid (600–1,200 mg),

Table 3. Daily dosages of orally applied vitamins, micronutrients, and other supplements

Vitamins		Micronutrients		Other			
A	retinol	10,000 IU	B	boron picolinate	2 mg	krill oil	1 g
B ₁	thiamine	30 mg	Ca	calcium citrate	300 mg	gingko extract	800 mg
B ₂	riboflavin-5-phosphate	20 mg	Cr	chromium chelidamate arginate	180 µg	melatonin	10 mg
B ₃	niacinamide	640 mg	K	potassium iodide	200 µg	l-tyrosine	200 mg
B ₅	Ca-pantothenate	380 mg	Mg	magnesium citrate	560 mg	ubiquinol	200 mg
B ₆	pyridoxal-5-phosphate	20 mg	Mn	manganese picolinate	4 mg	lithium	100 mg
B ₇	biotin	5 mg	Mo	molybdenum picolinate	200 µg	α-lipoic acid	600 mg
B ₉	methyltetrahydrofolate, glucosamine salt	1,000 mg	Se	selenomethionine	180 µg	acetyl-l-carnitine	2 g
				sodium selenite	300 µg		
B ₁₂	adenosylcobalamine	225 µg	Vn	vanadium picolinate	70 µg	acetylcysteine	1,000 mg
C	ascorbic acid	700 mg	Zn	zinc citrate, zinc picolinate	15 mg	astaxanthine	24 mg
D	cholecalciferol	10,000 IU				NADH	12 mg
E	α-tocopherol, all 8 isoforms	400 IU				taurine	1.5 g
K ₂	menaquinone 7	300 µg					

followed by sodium 2,3-dimercaptopropanesulfate (DMPS; 250 mg), together with potassium (6 mmol), magnesium (12 mmol), calcium (200 mg), and glutathione (GSH; 1,800 mg). Finally, after the DMPS infusion, sodium selenite (10–20 ml, 50 µg Se/ml) was i.v. injected separately. In addition to the i.v. infusion, DMPS (250 mg) was applied subcutaneously (s.c.) once per week. The treatment frequency was gradually reduced during therapy, resulting in 45 s.c. and 30 i.v. applications from March 26, 2013 until June 3, 2015. Until February 2, 2016, DMPS was applied orally 11 times (1 vial with 250 mg DMPS, mixed with 3 organic egg yolks, producing highly absorbable liposomal DMPS). Thus, overall, the patient received 86 DMPS applications.

In addition, the patient was advised to keep a vegetarian diet with a high proportion of raw, unprocessed food (60–70% of daily intake), also including wild herbs, and to reduce carbohydrate and especially gluten intake.

The patient's compliance with this therapy has been excellent. Motivated by the continuous improvement of his health, he has been following the instructions up to now.

Follow-up and Outcomes

Several laboratory investigations were performed to follow the therapy. The most important results are provided here.

Metals in the urine were determined in spot urine samples at the start of the chelation therapy, and after 1 and 2 months. The patient was asked to urinate before i.v. infusion of DMPS. About 45 min after finishing the infusion, urine was collected. For mercury, the first 2 measurements (4.3 and 3.9 µg/g creatinine, respectively) were below the reference value of 50 µg/g creatinine for DMPS challenge. Finally, in the third measurement, 1 month later and after 7 DMPS infusions, there was a strong increase in mercury to 248.4 µg/g creatinine. The high zinc values in the urine (3,130.6 to 6,581.8 µg/g creatinine, reference 2,000–9,000 µg/g creatinine) indicate that zinc was substituted successfully before and after the chelation therapy.

After the treatment of his teeth, already before the chelation therapy, the patient felt immediate relief. The muscular strength was increased, which he recognized by improvements when climbing stairs. Figure 1 shows the course of the most prominent findings during the 3 years of treatment. With the exception of the left shoulder muscle, the weakness diminished within 4 months after treatment start. The general health improved; the patient took up jogging and went to a gym regularly. He gained muscle mass and body weight. His performance in sports became even better than before the diagnosis of PMA. After 1.5 years, a neurologist confirmed the absence of ALS by EMG of the affected muscles.

Discussion

Comprehensive investigations led to the diagnosis of PMA based on:

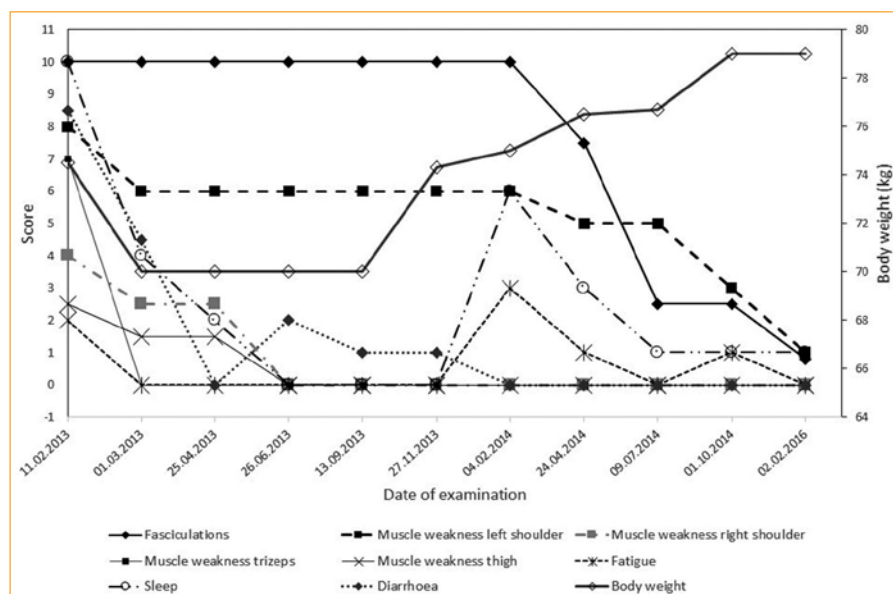
- clinical findings (weakness and fasciculations) in 2 body regions (shoulder and lower legs);
- EMG findings of denervation in 2 body regions (arms and legs) as well as
- bulbar signs in EMG (denervation of m. masseter).

PMA is distinguished from ALS by a lack of effects on the upper motor neuron. The close relationship of the 2 diseases is, however, reflected by the fact that upper motor neuron findings often appear at later stages of PMA, and degeneration of upper motor neurons is also found in the majority of PMA patients if autopsy is performed. In addition, patients with a PMA phenotype carry pathogenic mutations known from ALS. Therefore, PMA is considered to be a variant of ALS [9].

When evaluating the success of the therapy, it is also important to rule out misdiagnosis, because similar diseases might be better treatable than ALS. As described above, the diagnostic process was thorough and several alternative diagnoses to motor neuron diseases can be excluded, as summarized in table 2. A finding that is not typical of ALS is a slightly increased quotient of albumin in the spinal fluid/serum of 11.2×10^{-3} . A range of $6.5 \times 10^{-3} - 8 \times 10^{-3}$ is considered as normal at the age of the patient. For ALS patients, maximum values of 10×10^{-3} have been reported [10]. As this is the only parameter changed in the spinal fluid, a few diagnoses besides ALS may account for this finding. One of them is cervical spinal stenosis. As the patient had cervical spinal stenosis, this may have caused the observed albumin increases in the spinal fluid [11]. In addition, a reduced sensory nerve conduction velocity is not typical of ALS. According to Kollewe and Petri [12], however, it does not contradict this diagnosis.

To allow a consistent evaluation, it would have been desirable if the hospital that had first diagnosed the motor neuron disease had examined the patient after the therapy. This option was proposed

Fig. 1. Time course of improvement of symptoms during treatment. Scores were rated at 0–10, with 10 being the maximum; fasciculation and body weight were established independently or through measurement; all other variables were scored by the patient at every visit on a 10-point numerical rating scale.



several times to the patient. However, for personal reasons (as the physician told him that he will die in 1–2 years, the patient fell into a deep depression and considered suicide), the patient refrained from returning to this hospital but chose to see the resident neurologist who had first sent him to the hospital. The resident neurologist registered the absence of motor neuron disease in his EMG examinations, which can be taken as confirmation of the successful therapy.

There is also the possibility of spontaneous healing of motor neuron disease. In fact, there are a few reports that ALS may be reversible, even without therapy [13–15]. The temporal association of the improvements with the therapy in the case of our patient, however, argues against spontaneous healing. In addition, several other ALS patients have improved considerably after therapy initiated by J.M. based on a similar protocol.

In conclusion, we are confident that the patient had indeed suffered from motor neuron disease and that his healing was a consequence of the therapy.

The patient received a chelation therapy, to remove amalgam or other heavy metals originating from an assumed previous exposure, although no residual amalgam was detected during the investigation of the teeth, and although the levels of mercury and other metals in the hair and after the first 2 DMPS challenges were within the normal reference values. According to the experience of J.M., a chelation therapy is already justified when exposure, e.g., from unprotected removal of dental amalgam, has been established in a patient's history, even without measuring abnormal values through normal routes of human biomonitoring. This is backed by data showing that verified exposure to mercury can lead to neurological symptoms despite normal biomonitoring results [16, 17]. Furthermore, this approach is justified in hindsight by the fact that, finally, high mercury concentrations appeared in the urine of the patient during the chelation therapy, albeit with a delay of 2 months. The delay was probably due to an accumulation of mercury in deep

compartments like the brain or the spine, where it is not readily accessible [18]. Mercury accumulates in interneurons and to a lesser degree in α -motoneurons, in amounts increasing with age. This may lead to motor neuron death and thus provides support to the view that exposure to mercury may be a contributing factor to ALS in susceptible individuals [19].

There are reports in the literature showing that chelation therapy is capable of reducing ALS or ALS-like symptoms after exposure to mercury [20], but there are also cases without success [21]. The chelation therapy applied here is different from earlier approaches. First, it is applied over a long period. Generally, with prolonged DMPS application, several peaks of mercury are observed in the urine in humans previously exposed to mercury [22], which is possibly due to the redistribution of mercury from deep compartments into tissues that are accessible to DMPS [23–26]. As it is known that mercury accumulates as inorganic mercury in the brain, it is important to cover these deep compartments by an appropriate therapy. The numerous applications were well tolerated by the patient, which is consistent with the low toxicity of DMPS [27].

In addition, the chelation therapy involves α -lipoic acid. α -Lipoic acid enters the brain and reverses the oxidant effects of mercury [28], but it is not capable of removing mercury from the brain [26]. As it also has chelating properties, it may contribute to the elimination of mercury from other compartments of the body. Finally, selenium plays an important role in the therapy. Selenium effectively binds to mercury and reduces its toxicity [29, 30]. Thus, any remaining mercury that may not be bound to DMPS can be efficiently inactivated.

Another factor that may have contributed to the therapy is the intensive dental treatment aiming at removing residential amalgam, other metals, and inflammation. No amalgam was detected, but metal linings were restored and the osteitis under 2 teeth of the patient was cured. Osteitis – also called fatty degenerative osteone-

crisis, chronic ischemic bone disease, neuralgia-inducing cavitation osteonecrosis, or just jawbone cavitation – is characterized by hollow cavitations with soft tissue that have undergone fatty dystrophic changes, and by delamination of the bony sheath of the inferior alveolar nerve [31]. It may produce facial pain but can also be present for years as an asymptomatic process. Dramatically increased levels of RANTES and fibroblast growth factor 2 (FGF-2) can be detected in the fatty tissue removed by surgery, but no elevations in cytokines associated with acute inflammation [32, 33]. RANTES is increased in the serum of patients with several chronic diseases, including ALS [34]. Surgical debridement of the tissue in the cavitations has led in several cases to an improvement of the neuralgic pain in the face [35], and also of immunological complaints, such as rheumatic, allergic, and other inflammatory diseases [33]. The fact that the patient felt immediate relief after treatment of his teeth even before the start of the chelation therapy points to a possible contribution of this treatment to healing. Furthermore, according to the experience of J.M., major improvements in the disease status of his patients are observed if teeth are cured at the start of the therapy, which involves – sometimes – radical eliminations of teeth.

Psychotherapy was initiated by the patient after the start of the therapy as a support for the emotional problems associated with his disease and its interpersonal consequences. In his own view, however, this was not the major causative factor for his improvement.

In conclusion, the therapy described here is a promising approach to treating some kinds of motor neuron disease. It should be evaluated more widely and rigorously.

References

- Ludolph A, Drory V, Hardiman O, Nakano I, Ravits J, Robberecht W, Shefner J, WFN Research Group on ALS/MND: A revision of the El Escorial criteria – 2015. *Amyotroph Lateral Scler Frontotemporal Degener* 2015;16:291–292.
- Forsgren L, Almay BG, Holmgren G, Wall S: Epidemiology of motor neuron disease in northern Sweden. *Acta Neurol Scand* 1983;68:20–29.
- del Aguila MA, Longstreth WT Jr, McGuire V, Koepsell TD, van Belle G: Prognosis in amyotrophic lateral sclerosis: a population-based study. *Neurology* 2003;60:813–819.
- Ferraiuolo L, Kirby J, Grierson AJ, Sendtner M, Shaw PJ: Molecular pathways of motor neuron injury in amyotrophic lateral sclerosis. *Nat Rev Neurol* 2011;7:616–630.
- Deutsche Gesellschaft für Neurologie: Leitlinien für Diagnostik und Therapie in der Neurologie: Amyotrophe Lateralsklerose. *www.dgn.org*, 2012.
- Poppe L, Rue L, Robberecht W, Van Den Bosch L: Translating biological findings into new treatment strategies for amyotrophic lateral sclerosis (ALS). *Exp Neurol* 2014;262PB:138–151.
- Bedlack RS, Joyce N, Carter GT, Paganoni S, Karam C: Complementary and alternative therapies in amyotrophic lateral sclerosis. *Neurol Clin* 2015;33:909–936.
- Mutter J, Naumann J, Guethlin C: Elimination of xenobiotics in a female patient with fibromyalgia, chronic fatigue, and trunk obesity. *Forsch Komplementmed* 2007;14:39–44.
- Agosta F, Al-Chalabi A, Filippi M, Hardiman O, Kaji R, Meininger V, Nakano I, Shaw P, Shefner J, van den Berg LH, Ludolph A, WFN Research Group on ALS/MND: The El Escorial criteria: strengths and weaknesses. *Amyotroph Lateral Scler Frontotemporal Degener* 2015;16:1–7.
- Laborlexikon: Liquordiagnostik: Albumin-Quotient Liquor/Serum-Quotient. www.laborlexikon.de/Lexikon/Infoframe/II/Liquor-Diagnostik.html (last accessed May 4, 2017).
- Brettschneider J, Claus A, Kassubek J, Tumani H: Isolated blood-cerebrospinal fluid barrier dysfunction: prevalence and associated diseases. *J Neurol* 2005;252:1067–1073.
- Kollewe K, Petri S: Amyotrophe Lateralsklerose. *Klin Neurophysiol* 2009;40:3–16.
- Tsai CP, Ho HH, Yen DJ, Wang V, Lin KP, Liao KK, Wu ZA: Reversible motor neuron disease. *Eur Neurol* 1993;33:387–389.
- Tucker T, Layzer RB, Miller RG, Chad D: Subacute, reversible motor neuron disease. *Neurology* 1991;41:1541–1544.
- Vale TC: Reversible lower motor neuron disease: a new case of a forgotten disease. *J Neurol Res* 2013;3:40–41.
- Drasch G, Bose-O'Reilly S, Beinhoff C, Roeder G, Maydl S: The Mt. Diwata study on the Philippines 1999 – assessing mercury intoxication of the population by small scale gold mining. *Sci Total Environ* 2001;267:151–168.
- Drasch G, Bose-O'Reilly S, Maydl S, Roeder G: Scientific comment on the German Human Biological Monitoring values (HBM values) for mercury. *Int J Hyg Environ Health* 2002;205:509–512.
- Rooney JP: The retention time of inorganic mercury in the brain – a systematic review of the evidence. *Toxicol Appl Pharmacol* 2014;274:425–435.
- Pamphlett R, Kum Jew S: Age-related uptake of heavy metals in human spinal interneurons. *PLoS One* 2016;11:e0162260.
- Zhou Z, Zhang X, Cui F, Liu R, Dong Z, Wang X, Yu S: Subacute motor neuron hyperexcitability with mercury poisoning: a case series and literature review. *Eur Neurol* 2014;72:218–222.
- Praline J, Guennoc AM, Limousin N, Hallak H, de Toffol B, Corcia P: ALS and mercury intoxication: a relationship? *Clin Neurol Neurosurg* 2007;109:880–883.
- Gonzalez-Ramirez D, Zuniga-Charles M, Narro-Juarez A, Molina-Recio Y, Hurlbut KM, Dart RC, Aposhian HV: DMPS (2,3-dimercaptopropane-1-sulfonate, Dimaval) decreases the body burden of mercury in humans exposed to mercurous chloride. *J Pharmacol Exp Ther* 1998;287:8–12.
- Aposhian MM, Maiorino RM, Xu Z, Aposhian HV: Sodium 2,3-dimercapto-1-propanesulfonate (DMPS) treatment does not redistribute lead or mercury to the brain of rats. *Toxicology* 1996;109:49–55.

Patient's Perspective

The patient noted down his experiences during the diagnosis and treatment of his disease; the text is publicly available [36].

Informed Consent

The patient consented to anonymous publication of his data, which is gratefully acknowledged by the authors.

Author Contributions

I.M. conducted the review of the case and wrote the manuscript. J.M. developed and conducted the therapy and organized a large part of the data collection. He also contributed to writing the paper and critical discussions. H.W. generated the idea for the study, developed the protocol, and partook in writing the paper and in critical discussions.

Disclosure Statement

None of the authors has any conflict of interest.

- 24 Pingree SD, Simmonds PL, Woods JS: Effects of 2,3-dimercapto-1-propanesulfonic acid (DMPS) on tissue and urine mercury levels following prolonged methylmercury exposure in rats. *Toxicol Sci* 2001;61:224–233.
- 25 Gabard B: Distribution and excretion of the mercury chelating agent sodium 2,3-dimercaptopropane-1-sulfonate in the rat. *Arch Toxicol* 1978;39:289–298.
- 26 Aposhian HV, Morgan DL, Queen HLS, Maroin RM, Aposhian MM: Vitamin C, glutathione, or lipoic acid did not decrease brain or kidney mercury in rats exposed to mercury vapor. *J Toxicol Clin Toxicol* 2003;41:339–347.
- 27 Ruprecht J: Dimaval®. Scientific product monograph. Berlin, Heyl Chemisch-pharmazeutische Fabrik GmbH & Co. KG, 2008.
- 28 Anuradha B, Varalakshmi P: Protective role of DL-alpha-lipoic acid against mercury-induced neural lipid peroxidation. *Pharmacol Res* 1999;39:67–80.
- 29 Sakamoto M, Yasutake A, Kakita A, Ryufuku M, Chan HM, Yamamoto M, Oumi S, Kobayashi S, Watanabe C: Selenomethionine protects against neuronal degeneration by methylmercury in the developing rat cerebrum. *Environ Sci Technol* 2013;47:2862–2868.
- 30 Watanabe C: Modification of mercury toxicity by selenium: practical importance? *Tohoku J Exp Med* 2002;196:71–77.
- 31 Bouquot JE, Roberts AM, Person P, Christian J: Neuralgia-inducing cavitation osteonecrosis (NICO). *Oral Surg Oral Med Oral Pathol* 1992;73:307–319.
- 32 Lechner J, von Baehr V: RANTES and fibroblast growth factor 2 in jawbone cavitations: triggers for systemic disease? *Int J Gen Med* 2013;6:277–290.
- 33 Lechner J, Mayer W: Immune messengers in neuralgia inducing cavitation osteonecrosis (NICO) in jaw bone and systemic interference. *Eur J Integr Med* 2010;2:71–77.
- 34 Rentzos M, Nikolaou C, Rombos A, Boufidou F, Zoga M, Dimitrakopoulos A, Tsoutsou A, Vassilopoulos D: RANTES levels are elevated in serum and cerebrospinal fluid in patients with amyotrophic lateral sclerosis. *Amyotroph Lateral Scler* 2007;8:283–287.
- 35 Bouquot JE, Christian J: Long-term effects of jawbone curettage on the pain of facial neuralgia. *J Oral Maxillofac Surg* 1995;53:387–397.
- 36 Anonymus: Erfahrungsbericht bezügl. ALS. Tagesklinik Konstanz, 2015, p 4.